

# Therapeutic Potential of Tannic Acid in the Management of Polycystic Ovarian Syndrome (PCOS) in Letrozole Induced Rat Model: A Histological and a Biochemical Study

## Sıçanlarda Letrozol ile Oluşturulan Polikistik Over Sendromu (PKOS) Modelinde Tannik Asitin Terapötik Potansiyeli: Histolojik ve Biyokimyasal Çalışma

✉ Fatma Gumuskaya<sup>1,2</sup>, ✉ Tansel Sapmaz<sup>1</sup>, ✉ Halime Tuba Canbaz<sup>1</sup>, ✉ Sude Topkaraoglu<sup>1</sup>, ✉ Kubra Sevgin<sup>3</sup>, ✉ Muhammetnur Tekayev<sup>1</sup>, ✉ Selman Aktas<sup>4</sup>, ✉ Mahmud Esad Pence<sup>5</sup>, ✉ Oktay Irkorucu<sup>6</sup>

<sup>1</sup>University of Health Sciences Türkiye Hamidiye Faculty of Medicine, Department of Histology and Embryology, İstanbul, Türkiye

<sup>2</sup>Beykent University Faculty of Medicine, Department of Medical Services and Techniques, Program of Pathology Laboratory, İstanbul, Türkiye

<sup>3</sup>University of Health Sciences Türkiye Hamidiye International Faculty of Medicine, Department of Histology and Embryology, İstanbul, Türkiye

<sup>4</sup>University of Health Sciences Türkiye Hamidiye International Faculty of Medicine, Department of Biostatistics and Medical Informatics, İstanbul, Türkiye

<sup>5</sup>University of Health Sciences Türkiye, Ümraniye Training and Research Hospital, Clinic of Emergency Medicine, İstanbul, Türkiye

<sup>6</sup>University of Sharjah, College of Medicine, Department of Clinical Sciences, Sharjah, United Arab Emirates

### ABSTRACT

**Background:** To investigate the effects of tannic acid (TA) use on ovarian folliculogenesis, p53 expression, and serum luteinizing hormone (LH), follicle-stimulating hormone (FSH), and testosterone (T) levels in rats with polycystic ovary syndrome (PCOS) model.

**Materials and Methods:** A total of 18 Wistar female rats were used and divided into 3 experimental groups. Group 1 (G1, control), group 2 (G2, PCOS), group 3 (G3, PCOS+TA). Rats were induced with letrozole for 21 days to form a PCOS model. After 21 days, TA (40 mg/kg) was given by gavage for 10 days and the rats were sacrificed on the 10<sup>th</sup> day. PCOS formation was evaluated by daily estrous cycle follow-up. Hematoxylin & eosin and p53 immunohistochemical staining was performed on ovaries. Serum FSH, LH, and T levels were determined by ELISA. Data were analyzed with the One-Way ANOVA test and Kruskal-Wallis H test. P<0.05 was considered statistically significant.

**Results:** The number of cystic follicles was significantly increased in the PCOS group compared to the TA treatment group (p<0.05). The number of primary follicles was significantly increased in the TA treatment group (p<0.001). No significant change was observed in the number of primordial, secondary, and Graaf follicles between the experimental groups. A significant increase in LH and T was observed in the PCOS group (p<0.05). The increase in LH has significantly decreased TA administered rats (p<0.05). Although it was not significant, serum FSH level was increased in the PCOS+TA group. No immunoreactivity was detected in p53 staining in experimental groups.

**Conclusion:** TA can decrease cystic follicle formation and increase primary follicle formation in PCOS. Also, it can regulate the hormonal expression of serum LH, FSH, and T in PCOS-modeled rats.

**Keywords:** Letrozole, PCOS, rat, tannic acid



**Address for Correspondence:** Tansel Sapmaz, University of Health Sciences Türkiye Hamidiye Faculty of Medicine, Department of Histology and Embryology, İstanbul, Türkiye

Phone: +90 505 565 69 28 E-mail: sapmaz.tansel@gmail.com **ORCID ID:** orcid.org/0000-0002-7820-5837

**Received:** 29.03.2022 **Accepted:** 20.04.2022

**Amaç:** Polikistik over sendromu (PKOS) modeli oluşturulmuş sıçanlarda tannik asit (TA) kullanımının ovaryan folikülojenez, p53 ekspresyonu ve serum lüteinizan hormon (LH), folikül uyarıcı hormon (FSH) ve testosteron (T) seviyeleri üzerindeki etkilerini araştırmaktır.

**Gereç ve Yöntemler:** Toplam 18 Wistar dişi sıçan kullanıldı ve 3 deney grubuna ayrıldı: Grup 1 (G1, kontrol), grup 2 (G2, PKOS), grup 3 (G3, PKOS+TA). Sıçanlara, PCOS modeli oluşturmak için 21 gün boyunca letrozol verildi. Yirmi bir gün sonra TA (40 mg/kg) 10 gün boyunca gavaj yoluyla verildi ve sıçanlar 10. günde sakrifiye edildi. PKOS oluşumu günlük östrus döngüsü takibi ile değerlendirildi. Over dokusunda hematoksilen & eosin ve p53 immünohistokimyasal boyamaları yapıldı. Serum FSH, LH ve T seviyeleri ELISA ile belirlendi. Veriler One-Way ANOVA testi ve Kruskal-Wallis H testi ile analiz edildi.  $P<0,05$  istatistiksel olarak anlamlı kabul edildi.

**Bulgular:** PKOS grubunda kistik folikül sayısı TA tedavi grubuna göre anlamlı olarak arttı ( $p<0,05$ ). TA tedavi grubunda primer folikül sayısı anlamlı olarak arttı ( $p<0,001$ ). Deney grupları arasında primordial, sekonder ve Graaf foliküllerinin sayısında önemli bir değişiklik gözlenmedi. PKOS grubunda LH ve T'de anlamlı bir artış gözlemlendi ( $p<0,05$ ). TA uygulanan sıçanlarda LH seviyesinde önemli ölçüde azalma gözlemlendi ( $p<0,05$ ). PKOS+TA grubunda anlamlı olmasa da serum FSH düzeyi arttı. Deney gruplarında p53 boyamasında immünoreaktivite saptanmadı.

**Sonuç:** TA, PKOS'de kistik folikül oluşumunu azaltabilir ve primer folikül oluşumunu artırabilir. Ayrıca TA, PKOS modeli sıçanlarda serum LH, FSH ve T'nin hormonal ekspresyonunu düzenleyebilir.

**Anahtar Kelimeler:** Letrozol, PKOS, sıçan, tannik asit

## Introduction

Polycystic ovary syndrome (PCOS) is a complex metabolic disease characterized by chronic anovulation and hyperandrogenism, affecting 5-10% of women of reproductive age (1). It is a health problem with many clinical findings such as anovulation, amenorrhea, oligomenorrhea, menstrual irregularities, dysfunctional uterine bleeding, and hirsutism. More serious long-term risks are developing infertility, endometrial hyperplasia, endometrial cancer, dyslipidemia, coronary artery disease, and possible breast cancer (2). The chance of implantation of the embryo in the uterus of PCOS patients decreases (3). Abnormal endocrine and paracrine factors, metabolic dysfunctions, and changes in the microenvironment during folliculogenesis cause failure in the oocyte maturation and embryonic development in women with PCOS (4,5). Impaired oocyte sufficiency in PCOS is inevitably associated with abnormal follicle development. In PCOS patients, insulin resistance and paracrine disorder of growth factors, including transforming growth factor- $\beta$  disrupt the follicular environment. This changes the relationship between granulosa cells and oocytes and damages the cytoplasm of the oocyte and the nucleus maturation (6,7,8,9,10).

PCOS is characterized by abnormal secretion of gonadotropins (11). PCOS also is an increased synthesis of steroid hormones by the ovaries (11). In particular, the secretion of LH and T is increased in women with PCOS. The ratio of luteinizing hormone/follicle-stimulating hormone (LH/FSH) is elevated with PCOS, it results in the ovaries producing more androgens. Furthermore, in PCOS patients, the levels of insulin and insulin-like growth factors are elevated. This situation eventually increases the production

of androgens by follicular theca cells and enhances LH function (12). Apoptosis and the cellular proliferation ratio are essential for the normal physiological function of the body. However, this balance is disturbed in PCOS patients. Some factors are related to this syndrome, including the tumor regulatory gene, *p53* (13,14).

The most common secondary metabolites in plants are polyphenols and tannins are among the most widely studied phenolic compounds (15). Tannins are classified into hydrolyzed tannins and condensed tannins. Tannic acid (TA) is a kind of hydrolyzed tannin (16). Tannins have been reported to promote mammalian ovulation rate and embryo development (17). Also, TA prevents damage to biological molecules in the body by inhibiting hydroxyl radicals (18). TA has been accepted by the Food and Drug Administration as a safe chemical (19). TA can interact directly with biomacromolecules such as collagen, gelatin, and albumin due to its ability to form electrostatic interactions, hydrogen bonds, and hydrophobic interactions (20). Recently, it has been shown that TA can be used as an anti-cancer chemical in various animal cells (21). It has been shown that TA increases plasma androgen and estrogen in both pikas and root voles (22). It has been reported that low concentrations of tannins promote the *in vitro* embryo development of the mouse oocyte (23). However, there are very limited studies related to explaining why tannins could affect the reproduction of animals.

In the literature, there is no study demonstrating the effect of TA on experimental PCOS models in rats. The present study was carried out in an attempt to elucidate the effects of TA on letrozole-induced PCOS modelled rats with three main objectives. First, to determine whether TA administration in the PCOS model is correlated with

circulating LH, FSH, and T concentrations, and to determine whether TA can regulate the p53 expressions, and third, to determine whether TA can improve ovarian architecture and folliculogenesis in PCOS modeled rats.

## Material and Methods

The experimental study was performed in the laboratory of the Hamidiye Experimental Animals Production and Research Laboratory, University of Health Sciences Türkiye. Ethical approval of the project was obtained from the Hamidiye Animal Experiments Local Ethics Committee, University of Health Sciences Türkiye (no: 2019-03/01). All experimental animal procedures were performed following standard ethical guidelines. Scientific Research Projects Unit, University of Health Sciences Türkiye (no: 2019/071) supported this study.

### PCOS Model and Experimental Groups

A total of 18 female adult Wistar Albino rats weighing 170-250 g and 7-9 weeks old were used. The rats were drunk into city water and fed with standard pellet feed in a room with a 12-h light 12 hours dark photoperiod. The temperature was 21-23 °C. Rats in the estrus phase were determined by vaginal cytology follow-up. From the 10<sup>th</sup> day until the last day of the experiment, vaginal smear analysis was performed every day. The estrus cycle was followed by methylene blue staining. While examining the preparations, the result was reached by taking the cell structures as a reference (24). Weight control of experimental animals was done every day.

Letrozole was dissolved in 1 mL 0.5% carboxymethyl cellulose (CMC). All agents were given the gavage method. The rats were randomly divided into 3 prospective groups as follows:

The control group (n=6): The group in which 0.5% CMC was given every day during the experimental period.

PCOS group (n=6): The group in which 1 mg/kg/day letrozole® (FL24873, Cymit Química S.L., Spain) was given for 21 days then 1 mL of distilled water was given for 10 days.

PCOS+TA group (n=6): The group in which 1 mg/kg/day letrozole® was given for 21 days and then 40 mg/kg/day TA was given for 10 days.

### Histopathological Assessment

At the end of the experiment, 75 mg/kg ketasol and 10 mg/kg xylazine anesthesia were applied intraperitoneally to all rats. All rats were sacrificed by exsanguination and blood samples were collected via intracardiac way. The left ovaries of all the groups were isolated for histopathological assessment. The ovaries were fixed with 10% formaldehyde

for pathological examination and embedded in paraffin blocks after standard tissue processing. The blocks were sectioned with a thickness of 5 µm. Preparations were stained with HE and evaluated under light microscopy in terms of ovarian follicle number.

To assess ovarian architecture and follicle number, three sections of ovarian tissue were selected. Blinded observers evaluated the sections independently. Primordial, primary, secondary, graafian, and cystic follicles were counted as suggested by Souza et al. (25). Follicles were counted: As primordial follicle; surrounded by thin single layers of follicular epithelial cells surrounding the oocyte, primary follicle; the single or multilayered prismatic epithelium surrounding the oocyte, secondary follicle; follicle in which the oocyte is lined with more than two granulosa cells with a small antrum, graafian follicle; follicle containing a single large antrum, in which the oocyte is surrounded by some cumulus cells, cystic follicles; follicles with degrading granulosa cells in the thin layer of granulosa cells (26). The stained tissue samples were observed by a light microscope (Zeiss, Scope.A1, Germany).

### Immunohistochemistry (IHC) Staining of p53

Apoptosis of the cells was measured by IHC staining of p53 [Novocastra™ Liquid Mouse Monoclonal Antibody, p53 protein (DO-7), United Kingdom]. Deparaffinized ovary slides were rehydrated and incubated in citrate buffer for antibody retrieval. The slides were incubated in 3% of H<sub>2</sub>O<sub>2</sub> to quench the endogenous peroxidase activity. After blocking, slides were incubated with a p53 antibody at 4 °C overnight. Then, slides are incubated with biotinylated secondary antibodies, streptavidin-horseradish peroxidase, and DAB (3,3'-diaminobenzidine) on the next day. Counterstaining was performed with a hematoxylin solution for 5 min, and then slides were mounted after dehydration. The stained tissue samples were observed by a light microscope (Zeiss, Scope.A1, Germany).

### Biochemical Assessment

The blood was centrifuged at 12000 rpm for 10 minutes, serum samples were stored at -80 °C. Serum T (E0259Ra, BT Lab, Korea), FSH (EA0015Ra, BT Lab., Korea), and LH (E0179Ra, BT Lab., Korea) concentrations were measured by ELISA kits. The standard procedures were followed during ELISA measurements.

### Statistical Analysis

Statistical analysis of the data was performed with SPSS 25.0 (Statistical Package for the Social Sciences) program. The distribution of variables was analyzed using the Shapiro-Wilk test and normally distributed variables

were reported as mean  $\pm$  standard deviation and non-normally distributed variables were reported as median (minimum-maximum). Normally distributed variable groups were examined by the One-Way ANOVA test and non-normally distributed variable groups were examined with the Kruskal-Wallis H test. Within-group differences were examined using the Bonferroni correction. Different time measures of dependent variables were examined using the Repeated Measure ANOVA test.  $P < 0.05$  was considered statistically significant.

## Results

### Evaluation of the Estrous Cycle

The experiment was successful in all rats. Estrus cycles were determined by methylene blue staining (Figure 1A). Regular estrus cycles were observed in the vaginal smear preparations of rats belonging to the control (G1) group. Vaginal smear preparations from rats belonging to the PCOS group (G2) exhibited an irregular estrous cycle; mostly in the estrus phase. It was observed that the estrous cycle was regular in the PCOS+TA group.

### Evaluation of Body Weights

In all groups, the weight gain increased as the rat age increased weekly (Figure 1B). Accelerated weight gain was observed in the PCOS model group compared to the control and PCOS+TA group.

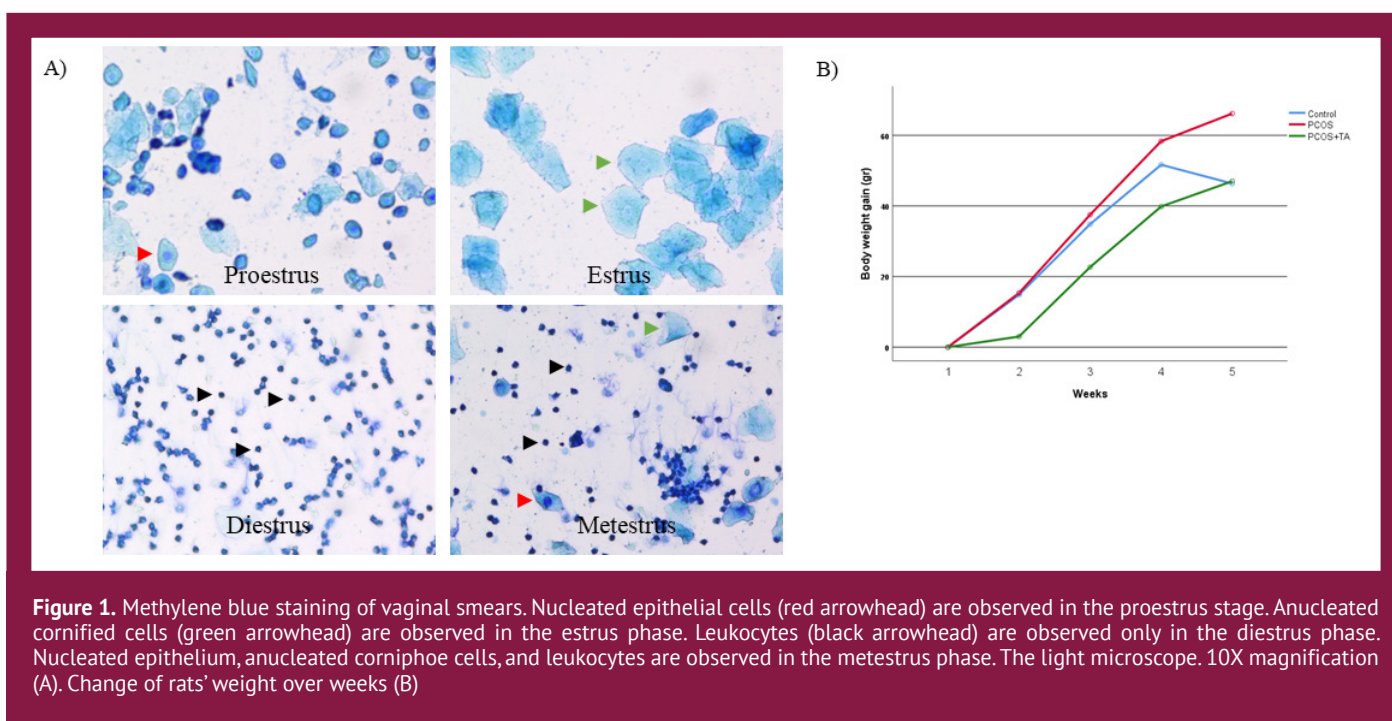
### Light Microscopy

Normal ovarian morphology was exhibited in the control group in the histopathological analysis. Many cystic follicles were present in the PCOS group. The ovarian tissue of letrozole-induced PCOS rats depicted cystic expansion, enlarged cystic sinus follicles, and decreased granulosa cell layers (Figure 2). The improved ovarian architecture was detected in the PCOS+TA group as indicated by the decreasing number of cystic follicles and an increasing number of graafian follicles in comparison to the PCOS group. It has been observed that treatment with TA reduced the theca cell layer, increased granulosa cell layers, and improved mature follicles in ovaries.

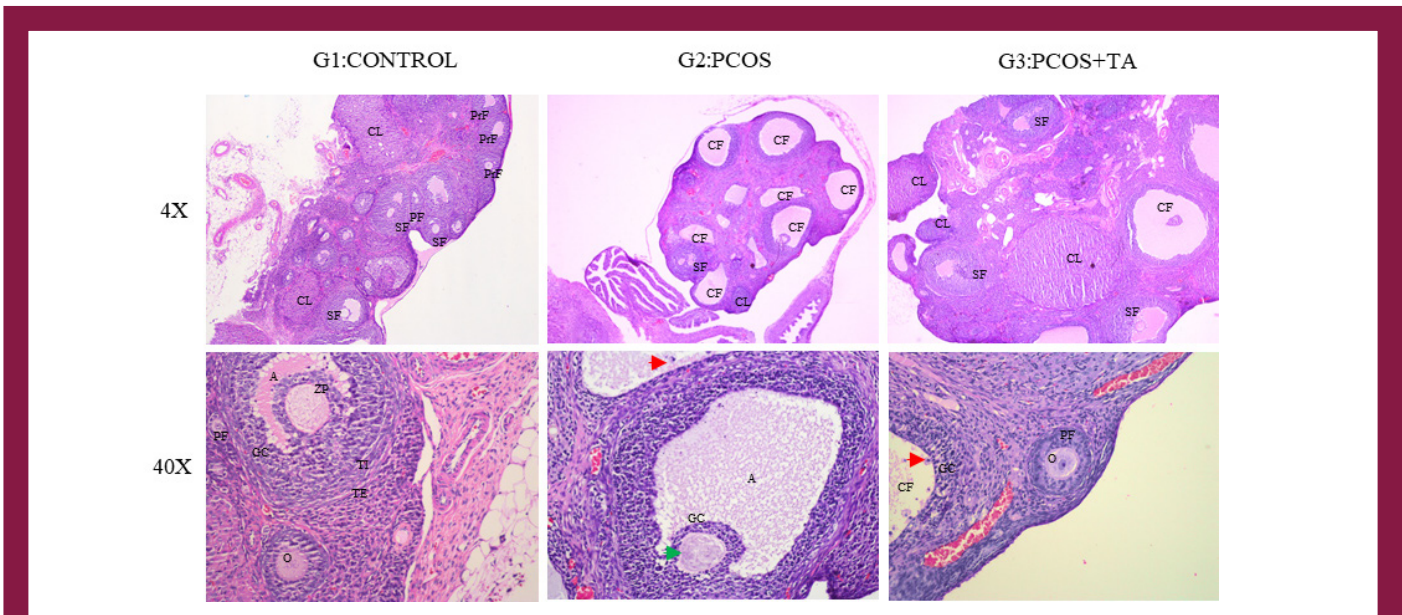
Table 1 shows the data of the primordial follicle, secondary follicle, Graaf follicle, and cystic follicle numbers. The number of cystic follicles was significantly increased in the PCOS group compared to the TA treatment group ( $p < 0.05$ ). The number of primary follicles was significantly increased in the TA treatment group compared to the PCOS group ( $p < 0.001$ ). No significant change was observed in the number of primordial, secondary, and Graaf follicles between the experimental groups. Light microscopic results supported the analysis of follicular count (Figure 2).

### IHC Staining of p53

Apoptosis was determined by assessing the expression of p53 (Figure 3). The p53 immunoreactivity in the ovaries of all animals belonging to the control and experimental groups was examined.







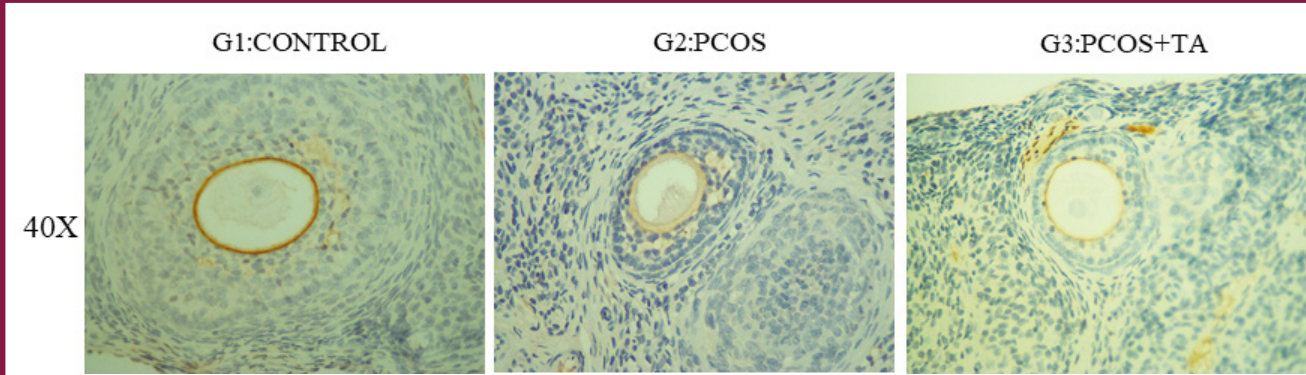
**Figure 2.** Histological assessment of the ovary. The control group (G1) with normal ovarian cortex structure. The cortex area exhibited the normal developing follicles with arranged PFs (G1, 4X). Theca and granulosa cells depicted regular and intact organization (G1, 40X). No the degeneration was observed in the oocyte and surrounding zona pellucida cells (G1, 40X). PCOS and the PCOS+TA groups exhibited cystic follicles. PCOS group displayed a few corpus luteum compared to other groups (G2, 4X). Also, layers of granulosa cells were decreased (G2, 40X). Apoptotic granulosa cells with pycnotic nuclei (red arrowhead), a marker of follicle atresia, were observed in the PCOS and PCOS+TA groups. At the same time, degeneration of oocyte and zona pellucida was detected (green arrowhead) (G2, 40X). In the Tannic Acid treatment group, oocyte and surrounding zona pellucida were normal and intact in some follicles (G3, 40X). Cystic follicles were also present in the TA group (G3, 4X). G1: Control, G2: PCOS, G3: PCOS+TA.

A: Antrum, PF: Primordial follicle, SF: Secondary follicle, GC: Granulosa cell, O: Oocyte, TC: Theca cells, PrF: Primary follicle, PCOS: Polycystic Ovary syndrome, CF: Cystic follicle, TA: Tannic acid. Light microscope. HE, 4X, 40X magnification

**Table 1.** Mean  $\pm$  SD of the primordial follicle, graaf follicle, and cystic follicle values and median (min-max) of the secondary follicle, and corpus luteum values in control, PCOS, and TA treated rats

		Statistic	p	Difference	
Primordial follicle	Control	Mean $\pm$ SD	4.5 $\pm$ 2.81	0.168 <sup>a</sup>	No difference
	PCOS		1.50 $\pm$ 1.51		
	PCOS+TA		3.50 $\pm$ 2.07		
Primary follicle	Control	Median (min-max)	5.50 (5-10)	0.008 <sup>b</sup>	PCOS+TA>PCOS
	PCOS		3.50 (2-6)		
	PCOS+TA		7 (6-12)		
Secondary follicle	Control	Median (min-max)	3 (2-9)	0.454 <sup>b</sup>	No difference
	PCOS		2 (2-5)		
	PCOS+TA		3.5 (1-7)		
Graaf follicle	Control	Mean $\pm$ SD	2 $\pm$ 1.41	0.086 <sup>a</sup>	No difference
	PCOS		0.83 $\pm$ 0.76		
	PCOS+TA		1.67 $\pm$ 0.81		
Cystic follicle	Control	Median (min-max)	2.5 (1-4)	0.017 <sup>b</sup>	PCOS>PCOS+TA
	PCOS		3.5 (3-4)		
	PCOS+TA		2 (1-3)		

PCOS: Polycystic ovary syndrome, SD: Standard deviation, TA: Tannic acid, <sup>a</sup>: ANOVA, <sup>b</sup>: Kruskal-Wallis H test



**Figure 3.** P53 immunohistochemical staining. There was a false positive in some areas but overall, no staining was detected. No difference was observed between the groups. G1: Control, G2: PCOS, G3: PCOS+TA. The light microscope. 40X magnification

PCOS: Polycystic ovary syndrome, TA: Tannic acid

**Table 2. Examination of biochemical parameters (LH, FSH, T) between experimental groups**

		Median (min-max)	Test statistic	p	Difference
<b>Testosterone</b>	Control	78.65 (40.97-107.98)	0.6351	0.042 <sup>a</sup>	PCOS>control
	PCOS	131.3 (68.78-149)			
	PCOS+TA	102.62 (25-120)			
<b>FSH</b>	Control	1.83 (1.53-2.63)	1.31	0.519 <sup>a</sup>	No difference
	PCOS	1.94 (1.80-2.17)			
	PCOS+TA	2.10 (1.78-2.23)			
<b>LH</b>	Control	1.04 (0.57-1.24)	11.789	0.003 <sup>a</sup>	PCOS>control PCOS>PCOS+TA
	PCOS	1.76 (1.67-1.93)			
	PCOS+TA	1.07 (1.00-1.64)			

PCOS: Polycystic ovary syndrome, TA: Tannic acid, FSH: Follicle-stimulating hormone, LH: Luteinizing hormone, T: Testosterone, <sup>a</sup>: Kruskal-Wallis H test

Immunoreactivity was not observed in any of the control and experimental groups. In the PCOS group, p53 staining in the nuclear areas was determined below 1%.

### Biochemical Assessment

Table 2 shows the results of the biochemical parameters. In terms of hormone LH and T levels, the PCOS group had a significant increase compared to the control group ( $p < 0.05$ ). The increase in LH was significantly decreased in the PCOS+TA group ( $p < 0.05$ ). Although it was not significant, serum FSH level was increased in the PCOS+TA group.

### Discussion

PCOS is a disease characterized by an androgen increase in the ovaries, ovulation disorder, and cystic structures in the ovaries (27). This endocrine disease affects 4-8% of women of reproductive age. 40% of women with PCOS are infertile due to anovulation disorder (28). The diagnosis of

PCOS is based on many criteria. PCOS treatment, causes, genetic transmission, roles of related genes, and gene regulation have not been fully elucidated (29). TA is an antioxidant compound, contains polyphenolic compounds, so it can mitigate various conditions of oxidative stress (30). In this study, we hypothesize that the administration of TA might have a potential curative effect against PCOS-modelled rat ovaries. To test this hypothesis, serum LH, FSH, and T levels, the number of follicles, and p53 expression were examined. Our study showed that 40 mg/kg TA treatment significantly decreased the number of cystic follicles. Also, although TA treatment cannot fully improve the p53 expression, it can control the hormone profile, the ovarian follicular cell architecture, and folliculogenesis in PCOS.

Since anovulation is one of the symptoms of PCOS, the estrous cycle of rats was followed by a vaginal smear examination. It has been previously reported that letrozole-

treated rats lost their regular estrus period (31). In our study, it was determined that the letrozole-administered rats exhibited an irregular estrous cycle, which depicts successful PCOS modeling. It was determined that letrozole caused prolongation of the estrus cycle in rats, apoptosis in granulosa cells, thinning of the membranes, and an increase in the number of antral follicles. In our study, it was determined that rats administered letrozole showed irregular and prolonged cycles and TA administration regulated the estrus cycle. These findings depicted that TA administration may control and regulate the estrus cyclicity in PCOS ovaries. Our findings are in accord with the literature (32).

Although obesity is not the only cause of PCOS, it plays a role in the pathophysiology of this disease. Glucose intolerance and insulin resistance have been found to be other causes of obesity in women with PCOS (33). In this study, the body weights of the rats were evaluated weekly, it was determined that the weights of the PCOS group increased in comparison to the control group. It was statistically determined that body weight gain decreased in the TA treatment group. These findings are consistent with previous studies in the literature (34).

To our knowledge, this study is the first report demonstrating a significant depletion in cystic follicles in the PCOS model by TA treatment. 40 mg/kg TA treatment decreased the elevated number of cystic follicles significantly in comparison to PCOS ( $p < 0.05$ ). These indicate the potential therapeutic effects of the TA treatment on the maintenance of folliculogenesis in the PCOS model (Table 1). Although no statistically significant difference was found, it was determined that the number of primordial follicles in the ovary was decreased in rats in the PCOS group. It was observed that the follicle reserve could not be preserved in the PCOS group due to the decrease in primordial follicular tissue, but it was preserved in the TA group. Furthermore, the number of cystic follicles was increased significantly in PCOS rats ( $p < 0.05$ ). The elevated number of cystic follicles is caused by hyperandrogenism (13). Since granulosa cells cannot transform into luteinized granulosa cells due to low FSH in PCOS, progesterone production and ovulation do not occur. A slowdown or hesitation at any stage of this mechanism causes the follicle to remain in the form of millimetric cysts in the ovaries. Therefore, with the monthly recurrence of these events, the number of millimetric cysts in the ovary increase (35). The effects of TA might be due to its potent antioxidant and anti-inflammatory properties. An increase in the number of primary follicle counts was significant in TA administered group compared to the PCOS group ( $p < 0.001$ ) (Table 1). In the PCOS group, the primary follicles were decreased; pointed out that some of these

follicles in the folliculogenesis process have undergone atresia or formed secondary follicles. This idea is consistent with the increased secondary follicle counts, especially in the PCOS group. In histopathological evaluation, letrozole-induced PCOS rats depicted cystic expansion, enlarged cystic sinus follicles, and decreased granular cell layers. These features are consistent with the pathological changes observed in human PCOS ovaries (Figure 2).

In PCOS patients, the secretion of LH and T is increased on the other hand FSH is decreased. When the LH/FSH ratio is elevated, the ovaries preferentially synthesize androgens. Therefore, PCOS-diagnosed women have higher levels of LH and T (36). In PCOS, ovulation does not occur due to low FSH and there is no progesterone production since granulosa cells cannot transform into luteinized granulosa cells (37). In this study, a significant increase in LH and T was observed in the PCOS group ( $p < 0.05$ ) (Table 2). The increase in LH significantly decreased TA administered rats ( $p < 0.05$ ) (Table 2). Serum T level was also decreased in TA administered rats. This reveals that TA can control the serum LH and T levels in PCOS modelled rats. No significant difference was observed in serum FSH levels. In humans, a decrease in serum FSH levels is seen in PCOS patients, but no statistical difference was observed in rats (38). Serum FSH level was increased in the PCOS+TA group. This suggests that TA can control FSH release in PCOS. Although it was not significant, a slight increase in serum FSH levels can be explained by an increase in FSH level at the very beginning of the prolonged estrus phase in PCOS rats (38).

The largest receptor group of apoptotic signals are molecules that have important roles in the cell cycle. One of the proteins that is best understood to control apoptosis is the p53 protein (39). The balanced ratio of cellular apoptosis and proliferation is disturbed in patients with PCOS. There is evidence that the cell's cycle-related tumor regulatory gene, p53, is responsible for the etiology of PCOS (13). The p53 has been demonstrated to play a role in granulosa cell apoptosis. Altered expression of p53 may contribute to the possible enhanced follicular resistance to apoptotic signals in PCOS (40). Cui et al. (41) investigated whether follicular dysplasia is associated with the regulation of apoptosis in ovarian granulosa cells. They showed that while the S phase was longer in the PCOS group in comparison to the control group, the G2/M phase was shorter in length and the cells in the PCOS group were subjected to apoptosis (41). In our study, an IHC study was applied to show the apoptotic cells in granulosa cells and to determine the effect of the p53 expression pattern on the pathogenesis of PCOS at the protein level. However, a significant immunopositivity could not be determined in immunohistochemical light microscopy examinations of p53 (Figure 3). This indicated



that PCOS follicles do not go atrophy. Also indicated that TA treatment cannot induce the apoptotic p53 mechanism.

### Study Limitations

The present study has certain limitations. The circulating LH, FSH, and T concentrations were measured as the final outcome, but it is not clear whether TA treatment concentration would successfully regulate pregnancy. Furthermore, the present study failed to show whether low or high TA treatment is more important in controlling hormonal disturbances. Also, as this was an animal study, the results could not be considered linear for humans.

### Conclusion

We observed that TA can alleviate histological disturbances in the PCOS model of rats. To the best of our knowledge, we reported for the first time that TA may be an effective and good alternative therapeutic agent in ameliorating PCOS histological disturbances and hormonal regulation. However, further studies are needed to confirm the safety of TA and its proper dose for PCOS treatment.

### Ethics

**Ethics Committee Approval:** Research Laboratory, University of Health Sciences Türkiye. Ethical approval of the project was obtained from the Hamidiye Animal Experiments Local Ethics Committee, University of Health Sciences Türkiye (no: 2019-03/01).

**Informed Consent:** All experimental animal procedures were performed following standard ethical guidelines.

**Peer-review:** Externally peer-reviewed.

### Authorship Contributions

Surgical and Medical Practices: F.G., M.T., S.A., Concept: F.G., T.S., H.T.C., S.T., K.S., O.I., Design: F.G., T.S., H.T.C., S.T., K.S., O.I., Data Collection or Processing: F.G., K.S., M.T., M.E.P., Analysis or Interpretation: F.G., K.S., S.A., Literature Search: F.G., T.S., H.T.C., S.T., K.S., O.I., Writing: T.S., H.T.C., S.T., K.S., O.I.

**Conflict of Interest:** No conflict of interest was declared by the authors.

**Financial Disclosure:** The authors declared that this study received no financial support.

### References

1. Franks S. Polycystic ovary syndrome. *N Engl J Med.* 1995;333:853-861. [\[Crossref\]](#)
2. Speroff L, Fritz MA. Eds. *Clinical gynecologic endocrinology and infertility.* Lippincott Williams & Wilkins; 2005. [\[Crossref\]](#)
3. Sarbassov DD, Ali SM, Kim DH, Guertin DA, Latek RR, Erdjument-Bromage H, et al. Rictor, a novel binding partner of mTOR, defines a rapamycin-insensitive and raptor-independent pathway that regulates the cytoskeleton. *Curr Biol.* 2004;14:1296-1302. [\[Crossref\]](#)
4. Franks S, Roberts R, Hardy K. Gonadotrophin regimens and oocyte quality in women with polycystic ovaries. *Reprod BioMed Online.* 2003;6:181-184. [\[Crossref\]](#)
5. Wood JR, Dumesic DA, Abbott DH, Strauss JF 3rd. Molecular abnormalities in oocytes from women with polycystic ovary syndrome revealed by microarray analysis. *J Clin Endocrinol Metab.* 2007;92:705-713. [\[Crossref\]](#)
6. Copp J, Manning G, Hunter T. TORC-specific phosphorylation of mammalian target of rapamycin (mTOR): phospho-Ser2481 is a marker for intact mTOR signaling complex 2. *Cancer Res.* 2009;69:1821-1827. [\[Crossref\]](#)
7. Yaba A, Bianchi V, Borini A, Johnson J. A putative mitotic checkpoint dependent on mTOR function controls cell proliferation and survival in ovarian granulosa cells. *Reprod Sci.* 2008;15:128-138. [\[Crossref\]](#)
8. Franks S, Stark J, Hardy K. Follicle dynamics and anovulation in polycystic ovary syndrome. *Hum Reprod Update.* 2008;14:367-378. [\[Crossref\]](#)
9. Elia E, Sander V, Luchetti CG, Solano ME, Di Girolamo G, Gonzalez C, et al. The mechanisms involved in the action of metformin in regulating ovarian function in hyperandrogenized mice. *Mol Hum Reprod.* 2006;12:475-481. [\[Crossref\]](#)
10. Sander VA, Facorro GB, Piehl L, Rubín de Celis E, Motta AB. Effect of DHEA and metformin on corpus luteum in mice. *Reproduction.* 2009;138:571-579. [\[Crossref\]](#)
11. Braillon A. Polycystic ovary syndrome. *N Engl J Med.* 2005;352:2756-2757. [\[Crossref\]](#)
12. Johansson J, Stener-Victorin E. Polycystic ovary syndrome: Effect and mechanisms of acupuncture for ovulation induction. *Evid Based Complement Alternat Med.* 2013;2013:762615. [\[Crossref\]](#)
13. Naseri L, Khazaei MR, Khazaei M. Synergic effect of bee pollen and metformin on proliferation and apoptosis of granulosa cells: Rat model of polycystic ovary syndrome. *J Food Biochem.* 2022;46:e13635.
14. Aksoy S, Armutcu F, Yiğitoglu MR. Using of caffeic acid phenetil ester (CAPE) the active substance of propolis in some neurologic disease and emergency. *Spatula DD.* 2011;1:37-42. [\[Crossref\]](#)
15. D'Archivio M, Filesi C, Di Benedetto R, Gargiulo R, Giovannini C, Masella R. Polyphenols, dietary sources and bioavailability. *Ann Ist Super Sanita.* 2007;43:348-361. [\[Crossref\]](#)
16. Zhao ZJ, Wang DH. Effects of diet quality on energy budgets and thermogenesis in Brandt's voles. *Comp Biochem Physiol A Mol Integr Physiol.* 2007;148:168-177. [\[Crossref\]](#)
17. Min BR, Fernandez JM, Barry TN, McNabb WC, Kemp PD. The effect of condensed tannins in *Lotus corniculatus* upon reproductive efficiency and wool production in ewes during autumn. *Anim Feed Sci Technol.* 2001;92:185-202. [\[Crossref\]](#)
18. Sen HM, Ozkan A, Guven M, Akman T, Aras AB, Sehitoglu I, et al. Effects of Tannic Acid on the Ischemic Brain Tissue of Rats. *Inflammation.* 2015;38:1624-1630. [\[Crossref\]](#)
19. Ahmad T. Reviewing the tannic acid mediated synthesis of metal nanoparticles. *Journal of Nanotechnology.* 2014;11:18-39. [\[Crossref\]](#)
20. Sahiner N, Sengel SB. Tannic acid decorated poly (methacrylic acid) micro and nanoparticles with controllable tannic acid release and antioxidant properties. *Colloids and Surfaces A: Physicochemical and Engineering Aspects.* 2016;508:30-38. [\[Crossref\]](#)
21. Sahiner N, Sagbas S, Aktas N, Silan C. Inherently antioxidant and antimicrobial tannic acid release from poly (tannic acid) nanoparticles with controllable degradability. *Colloids Surf B Biointerfaces.* 2016;142:334-343. [\[Crossref\]](#)
22. Dai X, Zou ZZ, Zhang TT, Jiang W, Wei WH, Yang SM. The effect of tannic acid on the gonad hormones in plateau pikas (*Ochotona curzoniae*) and root voles (*Microtus oeconomus*). *Acta Theriol Sinica.* 2011;31:278-283. [\[Crossref\]](#)



23. Spinaci M, Volpe S, De Ambrogi M, Tamanini C, Galeati G. Effects of epigallocatechin-3-gallate (EGCG)-on in vitro maturation and fertilization of porcine oocytes. *Theriogenology*. 2008;69:877-885. [\[Crossref\]](#)
24. Ekambaram G, Sampath Kumar SK, Joseph LD. Comparative Study on the Estimation of Estrous Cycle in Mice by Visual and Vaginal Lavage Method. *J Clin Diagn Res*. 2017;11:AC05-AC07. [\[Crossref\]](#)
25. Souza AZ, Fonseca AM, Izzo VM, Clauzet RM, Salvatore CA. Ovarian histology and function after total abdominal hysterectomy. *Obstet Gynecol*. 1986;68:847-849. [\[Crossref\]](#)
26. Wang F, Wang S, Zhang Z, Lin Q, Liu Y, Xiao Y, et al. Defective insulin signaling and the protective effects of dimethyldiguanide during follicular development in the ovaries of polycystic ovary syndrome. *Mol Med Rep*. 2017;16:8164-8170. [\[Crossref\]](#)
27. Sirmans SM, Pate KA. Epidemiology, diagnosis, and management of polycystic ovary syndrome. *Clin Epidemiol*. 2013;6:1-13. [\[Crossref\]](#)
28. Diamanti-Kandarakis E, Dunaif A. Insulin resistance and the polycystic ovary syndrome revisited: an update on mechanisms and implications. *Endocr Rev*. 2012;33:981-1030. [\[Crossref\]](#)
29. Witchel SF, Oberfield SE, Peña AS. Polycystic Ovary Syndrome: Pathophysiology, Presentation, and Treatment With Emphasis on Adolescent Girls. *J Endocrine Soc*. 2019;3:1545-1573. [\[Crossref\]](#)
30. Varanka Z, Rojik I, Varankal, Nemcsók J, Ábrahám M. Biochemical and morphological changes in carp liver following exposure to copper sulfate and tannic acid. *Comparative Biochemistry and Physiology Part C Toxicology & Pharmacology* 2001;128:467-478. [\[Crossref\]](#)
31. Jahan S, Abid A, Khalid S, Afsar T, Qurat-Ul-Ain, Shaheen G, et al. Therapeutic potentials of Quercetin in management of polycystic ovarian syndrome using Letrozole induced rat model: a histological and a biochemical study. *J Ovarian Res*. 2018;11:26. [\[Crossref\]](#)
32. Osuka S, Nakanishi N, Murase T, Nakamura T, Goto M, Iwase A, et al. Animal models of polycystic ovary syndrome: A review of hormone-induced rodent models focused on hypothalamus-pituitary-ovary axis and neuropeptides. *Reprod Med Biol*. 2018;18:151-160. [\[Crossref\]](#)
33. Aydos A, Oztemur Y, Dedeoglu BG. Polycystic ovary syndrome and molecular approaches. *Türk Hij Den Biyol Derg*. 2016;73:81-88. [\[Crossref\]](#)
34. Sun L, Ji C, Jin L, Bi Y, Feng W, Li P, et al. Effects of Exenatide on metabolic changes, sexual hormones, inflammatory cytokines, adipokines, and weight change in a DHEA-treated rat model. *Reprod Sci*. 2016;23:1242-1249. [\[Crossref\]](#)
35. Goodarzi MO, Azziz R. Diagnosis, epidemiology, and genetics of the polycystic ovary syndrome. *Best Pract Res Clin Endocrinol Metab*. 2006;20:193-205. [\[Crossref\]](#)
36. Hoseinpour MJ, Ghanbari A, Azad N, Zare A, Abdi S, Sajadi E, et al. Ulmus minor bark hydro-alcoholic extract ameliorates histological parameters and testosterone level in an experimental model of PCOS rats. *Endocr Regul*. 2019;53:146-153. [\[Crossref\]](#)
37. Joseph-Horne R, Mason H, Batty S, White D, Hillier S, Urquhart M, et al. Luteal phase progesterone excretion in ovulatory women with polycystic ovaries. *Hum Reprod*. 2002;17:1459-1463. [\[Crossref\]](#)
38. Miller BH, Takahashi JS. Central circadian control of female reproductive function. *Front Endocrinol (Lausanne)*. 2014;4:195. [\[Crossref\]](#)
39. Bennett MR, Littlewood TD, Schwartz SM, Weissberg PL. Increased sensitivity of human vascular smooth muscle cells from atherosclerotic plaques to p53-mediated apoptosis. *Circ Res*. 1997;81:591-599. [\[Crossref\]](#)
40. Homburg R, Amsterdam A. Polycystic ovary syndrome--loss of the apoptotic mechanism in the ovarian follicles? *J Endocrinol Invest*. 1998;21:552-557. [\[Crossref\]](#)
41. Cui X, Jing X, Wu X, Bi X, Liu J, Long Z, et al. Abnormal expression levels of BMP15/Smad1 are associated with granulosa cell apoptosis in patients with polycystic ovary syndrome. *Mol Med Rep*. 2017;16:8231-8236. [\[Crossref\]](#)